

# Registration evaluation of dynamic breast MR images

Andrew J. H. Mehnert, Pascal C. Bamford, and Andrew P. Bradley  
Centre for Sensor Signal and Information Processing  
The University of Queensland,  
Brisbane, Queensland, Australia  
{mehnert,bamford,bradley}@itee.uq.edu.au

Stephen Wilson, Ben Appleton, and Stuart Crozier  
School of Information Technology and Electrical Engineering  
The University of Queensland  
Brisbane, Queensland, Australia  
{wilson,appleton,stuart}@itee.uq.edu.au

Kerry McMahan and Dominic Kennedy  
Queensland X-Ray  
Greenslopes Private Hospital  
Greenslopes, Queensland, Australia

## Abstract

*The interpretation of dynamic contrast-enhanced breast MR images is predicated on the assumption of minimal voxel movement during the time course of the image acquisition. Misalignment of the dynamic image sequence as a result of movement during image acquisition can lead to potentially misleading diagnostic conclusions. In this paper a new methodology is presented for assessing the degree of in-plane (intra-slice) movement in a dynamic image sequence. The method is demonstrated on data from six subjects. The conclusion is that the method makes it possible to quantitatively qualify the accuracy of computed enhancement curves and more importantly to identify unacceptably poor registration.*

## 1. Introduction

Magnetic resonance (MR) imaging of the breast, before and after the administration of an extracellular gadolinium-containing contrast agent, can be used to detect and characterise breast diseases [1]. In particular the pattern of enhancement, i.e. the change in signal intensity over time, is an important criterion for the differentiation of malignant from benign lesions. MR examinations of the breast, and in particular dynamic contrast enhanced imaging, may re-

quire the subject to remain in the scanner for 30 minutes or more [1]. Misalignment of the dynamic image sequence as a result of movement during image acquisition can lead to errors in estimated enhancement curves and to potentially misleading diagnostic conclusions.

This paper presents a new methodology for assessing the degree of in-plane (intra-slice) registration (alignment) in a dynamic image sequence. The method is based on the automatic segmentation of the breast-air boundary (BAB) in each slice for each breast volume acquired over time, and the measurement of the mean absolute deviation between each postcontrast boundary and its corresponding precontrast boundary. Registration evaluation results are reported for six subjects who received a routine breast MRI examination.

## 2. Materials and methods

### 2.1. Image database

Image data from six subjects was used for this study. The data originates from routine breast MRI examinations performed by Queensland X-Ray, Greenslopes Private Hospital, Greenslopes, Queensland, Australia in the last five years. MRI examinations, of a single breast, were performed on a 1.5 T Signa EchoSpeed (GE Medical Systems, Milwaukee, USA) using an open breast coil which permit-

ted the subject to lie prone. A 3D dynamic scan using an SPGR sequence of TE = 1.5 ms, TR = 5.4 ms, 10 degree flip angle, and acquisition matrix size  $256 \times 256$  interpolated to  $512 \times 512$  (ZIP512) was typically used. Gadopentate dimeglumine, 0.2 mmol/kg, was administered manually at a rate of about 3 ml/s. The number of sagittal slices per volume acquired for each subject depended on the size of the breast and ranges from 22 to 48. The number of volumes per scan for each subject, including one precontrast volume, ranges from 6 to 11. Slice thicknesses, with 50% overlap (ZIP2), range from 2.2 to 5 mm. The resulting slice images are of size  $512 \times 512$  pixels with an 8-bit per pixel intensity scale.

Subjects with breast implants were deliberately excluded from this study. This was necessary to ensure that the results obtained using the proposed registration evaluation method could be cross-checked using an interactive method based on normalised cross-correlation (described in Section 2.4). This method requires that the region of pixels corresponding to the breast in a given slice image contains several heterogeneous areas. Unfortunately, for subjects with breast implants, this region of pixels is typically dominated by the implant which is relatively texturally homogeneous.

## 2.2. Breast/air boundary segmentation method

The breast/air boundary segmentation method (BABSM) we have devised is based on a *fast marching method* (FMM) [2]. The FMM is a numerical technique for tracking the evolution of a moving boundary and has several advantages over more traditional *deformable* (also called *active*) *contour methods* (DCMs) including:

1. the ability to model arbitrarily complex shapes;
2. the implicit ability to accommodate topological changes such as the splitting and merging of contours; and
3. not becoming trapped in a local energy minimum.

The BABSM consists of two stages: a coarse segmentation of a *mean volume* (MV), followed by a refined segmentation of each raw volume within the time series (precontrast volume, first postcontrast volume, etc.). The MV consists of a set of *mean slices* (MSs). The  $i$ -th MS is the pixel-wise mean of the  $i$ -th slice in all of the volumes. The MV thus has a higher signal-to-noise ratio than any single volume alone. The coarse segmentation stage proceeds as follows (see Figure 1):

1. the Canny edge detector [3] and elementary mathematical morphology [4] operations are used to obtain a rough estimate of the BAB in the middle MS;
2. this boundary is dilated to form a search space in which to apply the FMM;

3. within this search space, the magnitude of the directional gradient orthogonal to the boundary is computed (derived from the pixel-wise dot product of the gradient of the Euclidean distance transform (EDT) [4] of the pixels on and to the right of the boundary, and the gradient of the pixels in the middle MS); and
4. the FMM is applied.

The resulting contour is used to seed the segmentation of the preceding MS and the succeeding MS. These segmentations in turn seed segmentations backwards to the first MS and forwards to the last MS respectively. The refined segmentation stage uses the boundaries determined during the coarse segmentation to define search spaces for segmenting the individual slices of each raw volume. The segmentation is again based on a directional gradient and the FMM.

## 2.3. New registration evaluation method

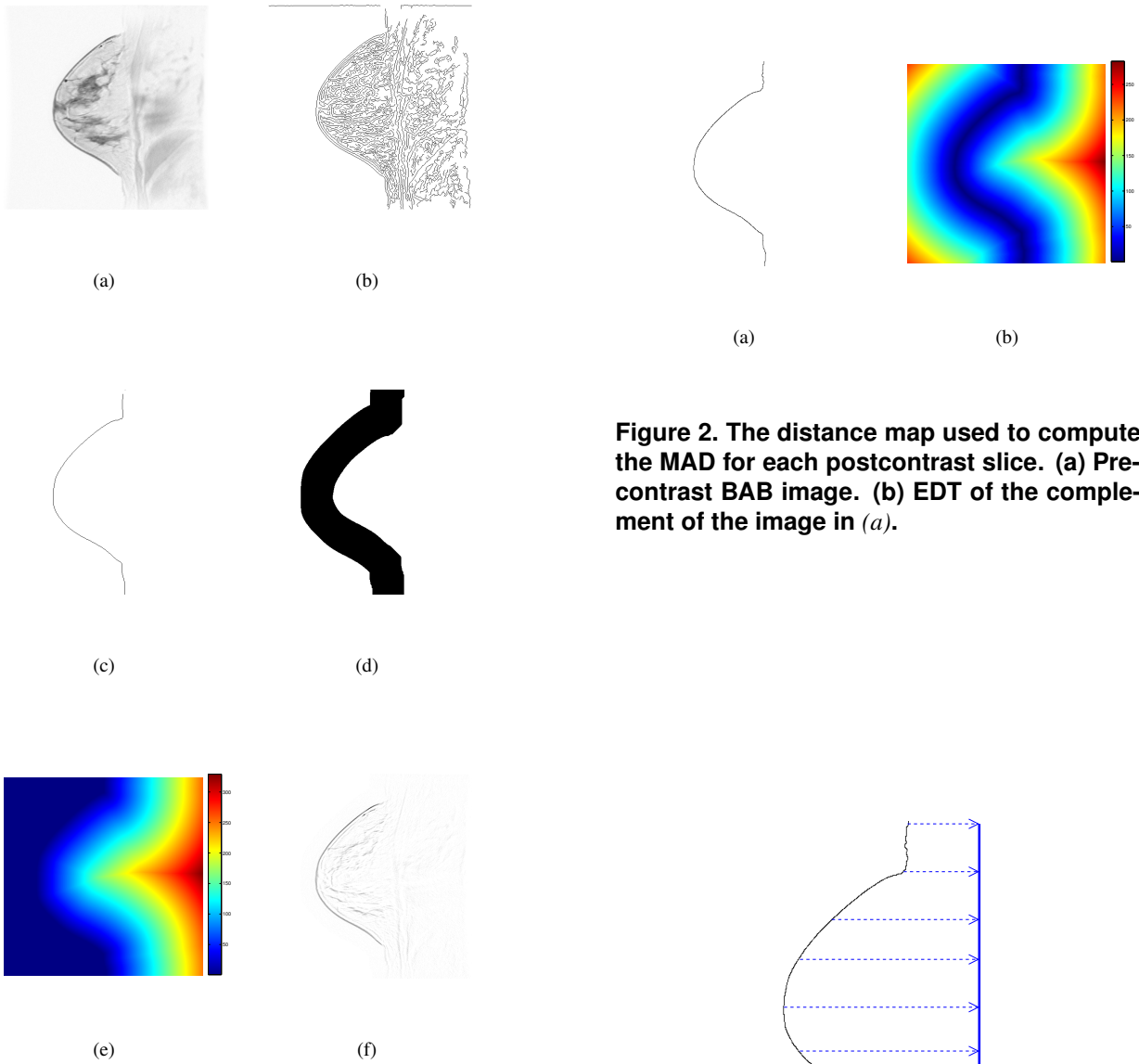
The method devised to evaluate the degree of registration (alignment) of a postcontrast slice with its corresponding precontrast slice is as follows:

1. The EDT of the complement of the BAB image for the precontrast slice is computed. This effectively assigns to each pixel its shortest distance to a BAB pixel (see Figure 2).
2. The BAB image for the postcontrast image is superimposed on the distance map computed in 1, and the mean of the coincident distance values is computed to yield the mean absolute deviation (MAD) from the precontrast BAB.

The coincident distance values on the postcontrast slice BAB can be projected onto a vertical line as shown in Figure 3. The idea can be extended to all of the postcontrast slices corresponding to the precontrast slice so that each horizontal projection is a maximum distance projection; i.e. along any horizontal line of projection, only the maximum of the set of distances on the BABs is projected. If this is done for all spatial slices, then it is possible to generate a two-dimensional deviation map consistent with a coronal projection of the breast (see Figure 6 in Section 3).

## 2.4. Validation based on normalised cross-correlation

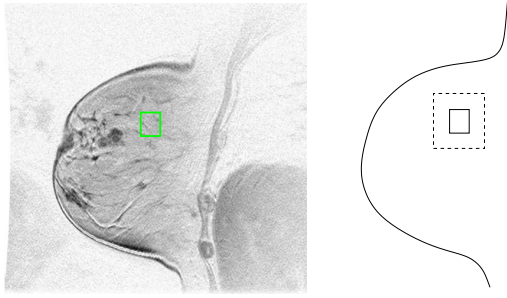
For the purpose of independently cross-checking the results obtained using the proposed registration evaluation method, an interactive method was devised based on *normalised two-dimensional cross-correlation* [5, 6, 7]. The method was implemented in MATLAB (The MathWorks,



**Figure 1. Initial segmentation steps. (a) Middle MS for Subject 1 (displayed as a photographic negative). (b) Result after the application of the Canny edge detector. (c) Result after morphological filtering. (d) Dilated boundary: search space for the FMM. (e) EDT of the pixels on and to the right of the boundary. (f) The directional gradient (displayed as a photographic negative) computed from the gradient of (a) and the gradient of (e).**

**Figure 2. The distance map used to compute the MAD for each postcontrast slice. (a) Pre-contrast BAB image. (b) EDT of the complement of the image in (a).**

**Figure 3. For a given postcontrast slice, the coincident distance values on the BAB can be projected onto a single line.**



**Figure 4. Left: User-selected ROI ( $60 \times 50$  pixels) in a precontrast slice. Right: The search window (dotted line) in which the best match is sought in each corresponding postcontrast slice.**

Inc., Natick, MA, USA). For a given postcontrast slice, the method evaluates the degree of registration with the corresponding precontrast slice as follows:

1. the precontrast slice image is displayed in a window;
2. the user is prompted to select a rectangular window (the template) within the breast that contains texture and/or structure;
3. the normalised cross-correlation is computed between the template and each window of corresponding size within a search window defined by extending the border of the template by forty pixels left, right, top, and bottom (see Figure 4);
4. the relative coordinates  $(\Delta x, \Delta y)$  of the template position that achieves the highest positive correlation coefficient is recorded;
5. the corresponding displacement

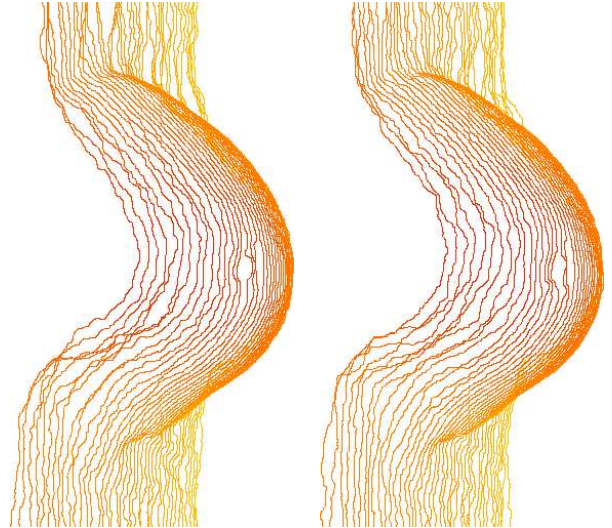
$$d = \sqrt{(\Delta x)^2 + (\Delta y)^2}$$

is computed;

6. steps 2 to 5 are repeated two more times; and
7. the mean,  $\bar{d}$ , of the three displacements is computed.

In this study, templates of mean size  $60 \times 50$  pixels were used. In addition, if the maximum positive correlation for any given template was less than 0.6 then the user was prompted to select another template (one with better defined texture and/or structure).

The quantity  $\bar{d}$ , like the MAD, is an estimate of the average in-slice movement manifest in a postcontrast slice.



**Figure 5. Example segmentation: first and seventh postcontrast volumes for Subject 1.**

### 3. Results

Figure 5 shows an example of the segmentation produced by the BABSMM (Subject 1, first and seventh postcontrast volumes). Figure 6 is the deviation map, produced using the new registration evaluation method described in Section 2.3, for the entire dynamic sequence for Subject 1. The plot shows a coronal view of the breast with each vertical strip corresponding to an individual slice in space. The colour at any given position signifies the maximum MAD at that point (over all volumes). Figure 7 shows the mean MAD for the middle three slices for each postcontrast volume for all six subjects. The observed deviation of less than two pixels (in-plane) was independently validated using the normalised cross-correlation method described in Section 2.4. This result supports the premise that the new registration evaluation method accurately measures in-plane movement. Figure 8 shows the distribution of the mean MAD (averaged over time) for all slices for all six subjects (slice numbering is relative to the middle slice). Our results indicate that within the main body of the breast, registration errors are typically on the order of only a couple of pixels (in-plane). This confirms the suitability of the MR examination protocol used to acquire these data. Larger deviations evident on the periphery, at the breast margins, are the result of segmentation variability because of noise and ill-defined gradient information in the image data.

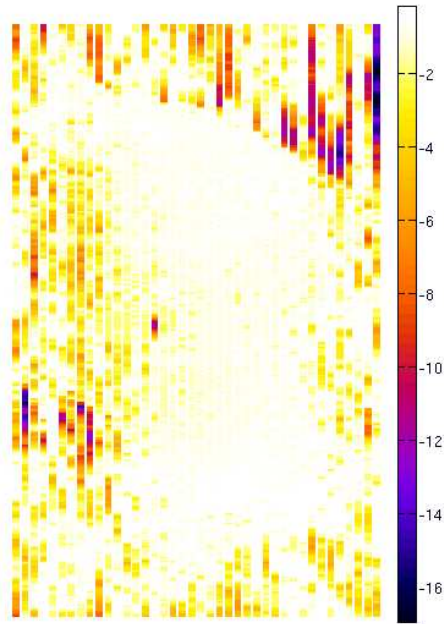


Figure 6. Deviation map for Subject 1.

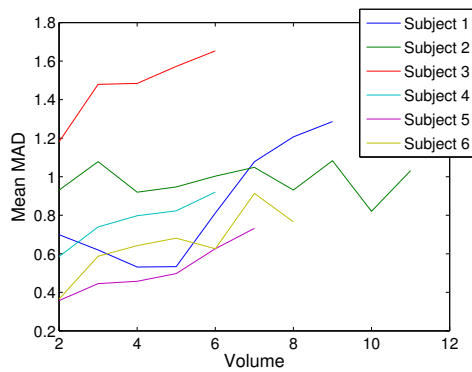


Figure 7. Deviation averaged over the middle three slices.

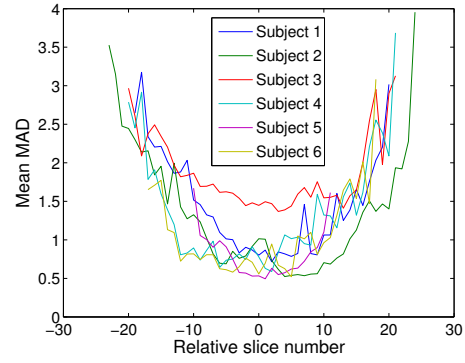


Figure 8. Deviation averaged over time.

#### 4. Summary and conclusion

In the routine clinical setting it is usually assumed that the degree of misalignment between successive breast image volumes in a dynamic contrast-enhanced image sequence is negligible and that computed enhancement curves are accurate. We have proposed a new registration evaluation method that makes it possible to quantitatively qualify this accuracy and more importantly to identify unacceptably poor registration (necessitating either a repeat scan or the need to employ some form of automated registration). The method is based on the automatic segmentation of the breast-air boundary in each slice for each breast volume acquired over time, and the measurement of the mean absolute deviation between each postcontrast boundary and its corresponding precontrast boundary. We applied the method to data from six subjects who received a routine breast MRI examination. The results were independently validated using an interactive procedure based on normalised cross-correlation. The results indicate that, for this set of data, in-plane movement is negligible. This confirms the suitability of the MR examination protocol used to acquire the data.

The efficacy of the proposed method needs to be evaluated on a larger database. This will be the subject of further research.

#### References

- [1] R. Warren and A. Coulthard, eds., *Breast MRI in practice*. London: Martin Dunitz, 2002.
- [2] J. A. Sethian, *Level set methods and fast marching methods: Evolving interfaces in computational geometry, fluid mechanics, computer vision, and materials science*. Cambridge, UK: Cambridge University Press, second ed., 1999.

- [3] J. Canny, "A computational approach to edge detection," *IEEE Transactions on Pattern Analysis and Machine Intelligence*, vol. 8, no. 6, pp. 679–698, 1986.
- [4] P. Soille, *Morphological image analysis: Principles and applications*. Berlin: Springer, second ed., 2003.
- [5] W. K. Pratt, *Digital image processing*. Wiley, second ed., 1991.
- [6] J. P. Lewis, "Fast template matching," in *Proceedings of Vision Interface 95*, (Quebec City), pp. 120–123, May 1995.
- [7] J. P. Lewis, "Fast normalized cross-correlation." <http://www.idiom.com/~zilla/Papers/nvisionInterface/nip.html>, 2005.